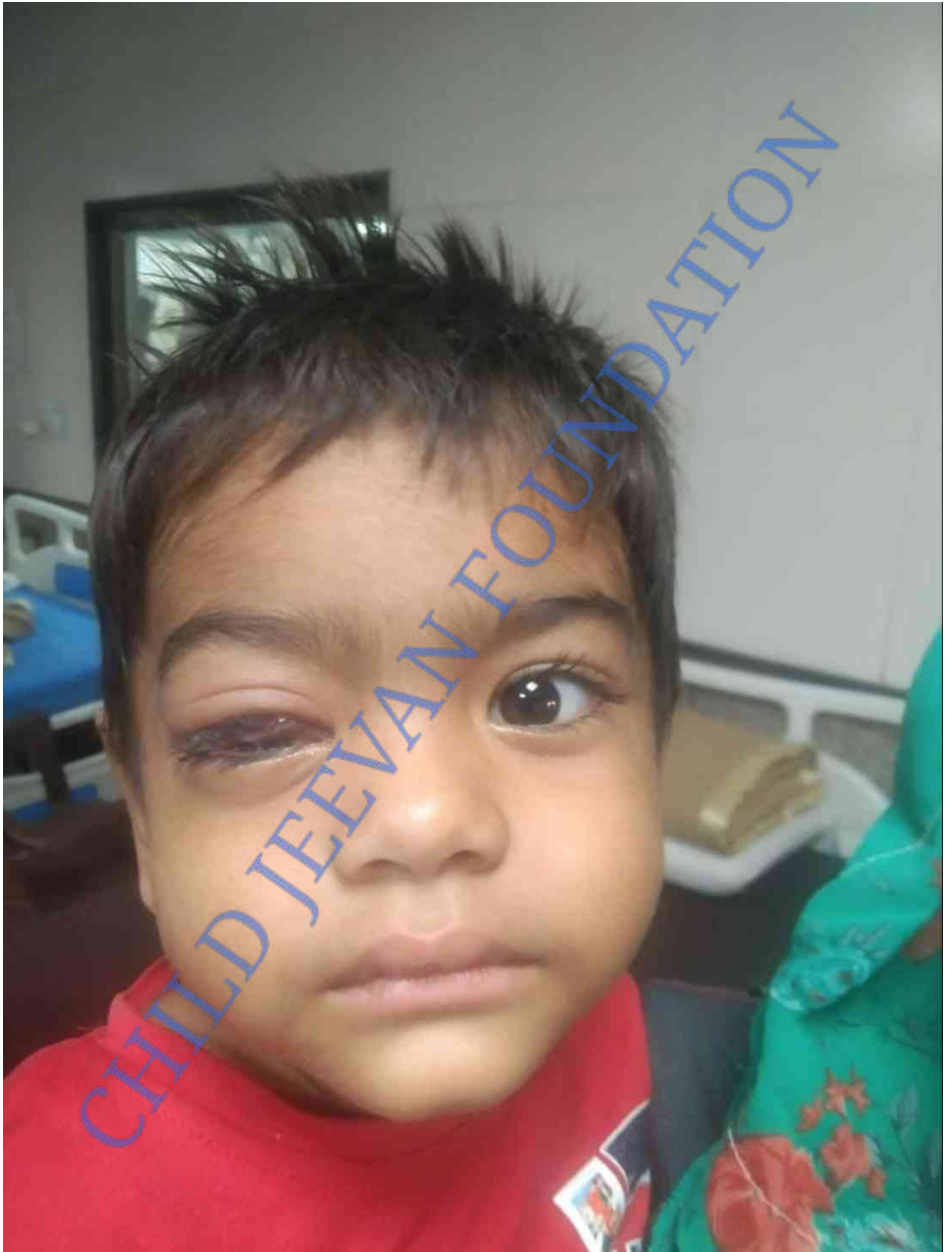





भारत सरकार
Government of India



बाल आधार

Aadhaar no. issued: 25/09/2025



अयांश जाटव
Ayansh Jatav
जन्म तिथि/DOB: 01/07/2023
पुरुष/ MALE

यह आधार 5 वर्ष की उम्र तक ही वैध है।

आधार पहचान का प्रमाण है, नागरिकता या जन्मतिथि का नहीं।
इसका उपयोग सत्यापन (ऑनलाइन प्रमाणीकरण, या क्यूआर कोड/
ऑफलाइन एक्सएमएल की स्कैनिंग) के साथ किया जाना चाहिए।
**Aadhaar is proof of identity, not of citizenship
or date of birth. It should be used with verification (online
authentication, or scanning of QR code / offline XML).**

2596 1940 9176

मेरा आधार, मेरी पहचान

D.L.No. : RLF21DL2023001584
RLF21DL2023001572

GST INVOICE

GST NO : 07AAGPH5319Q1ZV

HEALTH PLUS

Bare Space, Unpaid Concourse, Area-1, Line No.2, Gate No.2
AIIMS Metro Station, New Delhi - 110029

CREDIT CARD
ACCEPTED

Deals In : Medicines, Surgicals, Anti-cancer Drugs & Baby Care
& Health Care Products

ALL DAYS
OPEN

PHONE No. : +91-9718000479

* In case you find any inadvertent error in the price charged
Please bring this GST Invoice for refund of difference.

QTY.	PARTICULARS	HSN CODE	BATCH NO.	EXP. DT.	INC. GST%	AMOUNT
	SILICON BALL 16MM	30049099	0	00/00	5.0	1500.00
	SILICON BALL 16MM	40169990		00/00	5.0	1500.00
	SILICON BALL 20MM	40169990		00/00	5.0	1500.00
	CONFIRMER.	9018393		00/00	5.0	984.37
GST REVISED INVOICE						
Taxable	5,214.37	CGST	130.48	SGST	130.48	

BILL NO. : 72786 DATE : 16/12/25 MRP Total 5,484.37
Discount 4.37

Ms/Mr. : AYAN
PRESS BY DR. AIIMS
ADDRESS :

- 1. No Return, No Exchange Sign.
- 2. All Disputes are subject to Delhi Jurisdiction only.
- 3. Also Deals In Imported & Indian Drugs.

PROMPT SERVICE & REASONABLE RATES

GRAND TOTAL 5,480.00

CHAD DEVAN KOURI SHILTON

Printed by : CONTINENTAL FORAM (P) LTD. Ph : 011-5444212, info@continentalforam.in

E & O E

① PET → 22/1/26 (NPO → daycare 8am)

② TO give Chemo Cycle 2# post PET

③ Syp Septoran (5ml/40mg) 5ml alternate day

④ TO, cantids, RB₁ gene testing

⑤ Sibling Screening → 'TO, RPC'

⑥ IRCH Tue/Friday - (9am)

mtx (205) RT registration.

⑦ N/V CBC, U/T, RFT, 24/1/26

Iron profile
Vit D3
B₁₂/folate

⑧ ~~off~~ ~~protein~~ @ 8 ↓ milk
1 egg
1 fruit

Shravan
Dr PO

- N/V on Thursday at PCSC clinic at
2pm for film collectn + RC discussion
2/4/26

RC discussion - contrast
films not
available

Advised to get contrast MRI
done

Talked to Rameji Pantel

Get CEMRI Brain + orbit
(contrast scans to be done)

N/V on 8/4/26 to update
about contrast studies

9/4/26
Ayankh RC discussion -

Rt phthisis no ON involvement
left - TORB (size decreased)

7/3/26

EUA Done & Dr. Sumit / Dr. Chaudhri

F/U/G/O

(R) GpE RB

(L) GpC RB

S/P 30 Chemo

Last Chemo 10/2/26

OD

↳ Physiscal

OS



Partially Sclerified

Mass

Plan: F/U in old oncology clinic
1425 after 20 Chemo

↓
f/b Repeat

CEMRI Brain & Orbit Fat suppressed
Axial, Coronal & Saggital 2mm sections
through Optic Nv. & Pituitary Gland
to consider for (R) Enucleation

UID: 108714214
Dept. No: 20250050130215
Clinic. No: 2025 00 328
AVANSH JALAV
SO AJAY

Date: 13/04/2026
Ocular oncology - Dr. Dr.
SR. B. OC. V. R. 142 B
Med. IV MED
Room No.: 142

ARIPPA VILL - CHENNAI, PO - CHENNAI, RAOOORCHERY, PO - BAROOR,
TAMIL NADU, MADHYA PRADESH, INDIA
Mobile: 989503441



13/04/2026

- Ⓡ Group E RB (phthalical)
- Ⓛ Group C RB

S/P 40 SD-LEV (last - 20/3/26)

Paeds
Oncology clinic
opinion

→ cleared for Enucleation Ⓡ

get job enucleated
get Ⓡ Gr. E RB
Rate of admission 14/5/26

NMC
 All MRI films (Tues/53)
 10:00 AM.

[Signature]
13/04/2026

ward 2A
rd floor
8AM.

WARD 2-A
Dr. Shafali

CHILD JEEVAN FOUNDATION

9/4/26

40/w prof or. R seth

Advised for enucleation of Rt eye

~~histopathology~~

& further continue

~~Advised~~

9 cycles of adjuvant chemotherapy

Adv.

To

42 RPC,

kindly consider the patient for enucleation of Right eye & do current EVA to plan for further management

Kindly send appropriate

ON for Histopathology

to look for High risk features

Angals
SR

- N/V on 15/4/26 ~~with~~ after RPC consult

CHILD HEALTH FOUNDATION

- f/u in RPC clinic post 1 cycle of chemotherapy
 - N/V on Thursday ~~at~~ PCSC clinic at 2pm for film collectⁿ + RC discussion
- 2/4/26

RC discussion - contrast films not available

Anjali
Dr. ANJALI SARKAR
DM Senior Resident
Dept. of Pediatric Oncology

Advised to get contrast MRI done

Talked to Ranaji kantilal

Anjali
Dr. ANJALI SARKAR
DM Senior Resident
Dept. of Pediatric Oncology
AIIMS, New Delhi

Get CEMRI Brain + orbit (contrast scans to be done)

N/V on 8/4/26 to update about contrast studies

Chemo → check CBC / LFT / RFT

- Inj Emscit 2mg iv Push ^{Push to chemo}

- Inj Dexam 2mg iv Push

- Inj VCR 0.36mg iv Push

- Inj Carboplatin 400mg / 500ml NS over 2hrs

- Inj Etoposide 170mg in 500ml NS over 3hrs

- Post chemo

- Syb Emscit (mg / smt) 5ml TDS

- Tab Dexam (mg / tab) 1/2 Tab BID ^{3days}

Inj GCST 50mg sc x 5 days

→ Dated for Emucida 12/1/26.

CHILD JEEMAN FOUNDATION



Repeat MRI on 24/11/23 ↓

no significant \downarrow in soft tissue volume
Enhancement \downarrow from before. but

Optic nerve enhancement (+)

likely due to
Asymptomatic
cellulitis

to take as TORB

If any doubt repeat MRI.

WT = 10 kg
Height = 85 cm

Place

CIDW Proj R seth

① Repeat Optic review EUA

② Repeat CE MRI / Brain / Orbit

③ To take data for
EORB / Metastatic workup

oblique
Sagittal
coronal
Axial

④ Repeat MRI to discuss

⑤ to start urgent chem therapy
on Friday 2/1/2026

Dr. VISHAKHA VARSHNEY
SR. Pediatric Oncology
Dept. of Pediatrics
AIIMS, New Delhi

after discussion on Thursday

⑥ to bring child tomorrow 7/1/2026 at
2pm

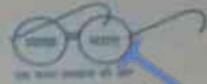BMBx + CSF + BMA / data

Dr. VISHAKHA VARSHNEY
SR. Pediatric Oncology
Dept. of Pediatrics
AIIMS, New Delhi



अ० भा० आ० सं० अस्पताल / A.I.I.M.S. HOSPITAL
बहिरंग रोगी विभाग / Out Patient Department

उपचार के अन्दर धूम्रपान पाना है। / SMOKING IS PROHIBITED IN HOSPITAL PREMISES



OPR-6

रोगी / Unit

विभाग / Dept.

अस्पताल संकेत सं./O.P.D. Regn. No.

नाम / Name	पिता/पुत्र/पत्नी/पुत्री F/S/W/D of	लिंग Sex	उम्र Age	पता / Address
Ayush		स्त्री	F	10871424

रिपोर्ट / Diagnosis

दिनांक / Date

उपचार / Treatment

LC01012501093 108714214



LC0101251736 108714214



Mr. AYAN JHATAV

5

30/12/25

To Carotids

1 centrally bulbous

CE MRI

Brain scan

(contrast)

1 Sagittal

2 Axial

3 coronal plain

urgent report

Dr. VISHAKHA VARSHNEY
Department of Pediatrics
All India Institute of Medical Sciences, New Delhi-110029

Dr. VISHAKHA VARSHNEY
SR, Paediatric Oncology
Dept. of Paediatrics
All India Institute of Medical Sciences, New Delhi



CLEAN AND GREEN AIIMS / एम्स का यही संकल्प, स्वच्छता से काया कल्प

अंगदान-जीवन का बहुमूल्य उपहार / ORGAN DONATION - A GIFT OF LIFE

O.R.B.O., AIIMS, 26588360, 26593444, www.orbo.org Helpline - 1060 (24 hrs service)



11/2/26

- Oral Care explained
- Sitz bath
- Personal hygiene
- No fresh complaints

$$\begin{array}{r} 2560 \\ 9.6 \overline{) 3830} \\ \underline{3830} \\ 0 \end{array}$$
 1.56 @
 LFT/RT - OK

11 kg. 18/2/26
19/2/26

Take MRI
 date
 to plan Emet 2y
 ↓ RPC

C/O Bilateral RB.

- Ⓜ EORB.
- Ⓜ GPC IORB.

post #2 HDCEV ∴ 25/1/26

Due for next # on/after.

15/2/26

No fresh complaints.

Adv take d/f #3.

- Pre chew
 - Iy. Dexa 2 y + Emet 2y IV

• chew

- Iy. VCR 0.3 y. IV

- Iy. Carboplatin 300y/100mls IV.

- Iy. Etoposide 130 y/500ml IV

• post chew

- Teab Dexa 2y OD.

- syp Emet 5cl TDS } x3d

- Iy. G-C8F 60 mg se OD

D_A - D₁₁.

- PHU c CB, LFT/RT

7/3/26

9


CHILD JEEVAN FUNDATION

Date:

NRG Discussion:
22/11/21

Dr Adnan Prof Khamees / Dr Lami
Dr Deep / Dr Zaki

Ac: HUCLO B/L RB c(R) gp E c orbit
OD
any chemosis cornea clear
R flat - NO NVI
Duo.



(RE) Group RB

USG 4E AT = 3.77mm
LBD = 16.34mm

(L) ap ERB
CEMRI ^{coronal} ^{sagittal} ^{axial} ^{Brain} ^{orbit}
2mm section through
optic nerve & pituitary gland
fat suppressed

- ed conjunctiva OD
- ed HA 2% BD
- ed occul. DBD
- anterior chemosis

RA Reyles f chemia in old
RB clino 143 2pm
WGL


CHILD DEVAN FOUNDATION

Date:

NRG Discussion:
22/11/20

Q: A direct hpf Rheumoid Arteritis
Ar Deep / Ar Late

AI: HUCLO B/L RB c (R) gp E exhibit
OD scleritis.
any chemosis cernu-clear
R flat - w NVI
[scribble]



(R) Group RB

USG HEAT = 7.71mm
LSD = 16.34mm

(L) ap ERB

CEMRI < coronal
fat suppressed
Brain sagittal
orbit Axial

2mm section through
optic nerve & parietal
gland
fat suppressed

also

- old wiffloxid SID
- old HA 2% BD
- old occipal-DBD

R/E -

- anterior chemu cycles

HA & cycles pchemu in old
RB clino 143 2pm
wgl

9/4/26

cop/w Prof Dr. R Setti

Advised for enucleation of Rt eye

~~histopathology~~

& further continue

~~Adjuvant therapy~~

9 cycles of adjuvant
chemotherapy

Adv.

To
4/2 RPC,

Kindly consider the patient for
enucleation of Right eye & do
current EVA to plan for
further management

Kindly send appropriate
ON for Histopathology

to look for High risk features

Angalis
SR

- N/v on 15/4/26 ~~with~~ after RPC consult

- flu in RPC clinic post 1 cycle of chemotherapy
 - N/V on Thursday ~~at~~ PCSC clinic at 2pm for film collectⁿ + RC discussion
- 2/4/26

RC discussion - contrast films not available

Dr. Anjali Bhatia
DM Senior Resident
Dept. of Pediatric Oncology
AIIMS, New Delhi

Advised to get contrast MRI done

Talked to Renuji cancelled

Dr. Anjali Bhatia
DM Senior Resident
Dept. of Pediatric Oncology
AIIMS, New Delhi

Get CEMRI Brain + orbit
(contrast scans to be done)

N/V on 8/4/26 to update about contrast studies

Sample ID : 26031810
Registration Date : 17/03/2026 02:48 PM
Report Date : 17/03/2026 04:03 PM
Aadhar Card



To check RFT / LFT prior to chemo

Sy. Emset 2 mg + sy. Dexam 2 mg
Now IV flush.

Sy. Vincristine 0.4 mg slow IV flush - D1

Sy. Carboplatin 400 mg in 100ml NS
IV once the - D1

- Sy. Etoposide 170 mg / 200ml NS IV
once the - D1/D2

Sy. G-CSF 60 mg SC q 24hly

DS till ANC recovery.

Cont. Aya Septan / SB / Bq

- date for chemo - Monica ji

- N/V in OPD - 28/1/2026 - CBC / RFT / UTT.

- MRI films

Shivani
S

- flu in RPC clinic post 1 cycle of chemotherapy
 - N/V on Thursday ~~at~~ PCSC clinic at 2pm for film collectn + RC discussion
- 2/4/26

RC discussion - contrast films not available

Anjali
Dr. ANJALI BARKER
DM Senior Resident
Dept. of Pediatric Oncology
SMS, New Delhi

Advised to get contrast MRI done

Talked to Rameshji Cantid

Anjali
Dr. ANJALI BARKER
DM Senior Resident
Dept. of Pediatric Oncology
SMS, New Delhi

Get CEMRI Brain + orbit (contrast to scans to be done)

N/V on 8/4/26 to update about contrast studies

CHILD JEEVAN FOUNDATION

23/4/26

D/F Admission De brustel
Ad

Admet 2. (2) Scumbate
(2) EUA

14/5/26

Regrets No beds

→ DOA: 11/6/26 | Ward 2A | 8m

D/F EUA: 16/5/26 | 7th Floor | 7:30am

NPO explained Solids 8hr (12am)
Semi-solids 6hr (2am)
Liq 4hr (4am)

CHILD JEEVAN FOUNDATION

CK-114430



अ० भा० आ० सं० अस्पताल / A.I.I.M.S. HOSPITAL
बहिरंग रोगी विभाग / Out Patient Department

अस्पताल में अग्नि प्रयोग मना है। / SMOKING IS PROHIBITED IN HOSPITAL PREMISES

सिद्धि विभाग
UHID: 108714214

कमरा / Room
C-210

OPR-6

Queue / संख्या
N9

Dept No: 20250030035069

ANSH JATAV

MAJAY
1M 28D / M(पूर्व)

CHHIRETA, PO- CHHATA,
KOUNIKHURD, PO- BARONI DISTT.
745000
General Rs. 0

Patient



Reporting: 02/23/25
29/12/2025

वर्गीकृत सं./O.P.D. Regn. No.

Age

Address

/Diagnosis

F/U/C/O B/L RB (R) grp E \bar{c} orbital Cellulitis

दिनांक/Date

उपचार/Treatment

(L) grp C RB

- Swelling of eye reduced. (Significantly) \rightarrow received ABX 3 weeks Augmentin

C/O (R) eye swelling 2 mo. \bar{c} blepharitis

(R) ON Intra-orbital Involvement Soft tissue \bar{c} cavernous sinus

RC discussed \bar{c} Dr Suli

time \rightarrow 4/11/25 \rightarrow
R1

Pre-septal soft tissue edema
All coats of the eye inflamed
ON enhancement \bar{c} orbital part (+)

Involvement